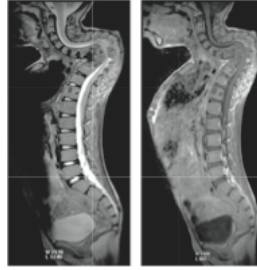
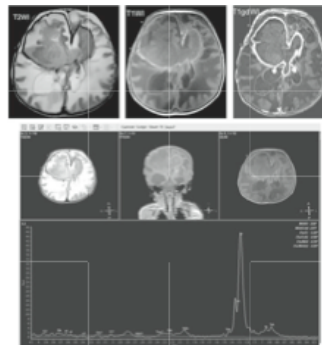




## Tuberculosis in Cambodian children A legacy of the Khmer Rouge



This 10-year-old boy suffers from deformities of the spine due to tuberculosis. The diagnosis of tuberculosis was confirmed by examining the abscesses, which extend as far down as the thigh, by means of MRI/MRS. It was our idea to apply this technology as a non-invasive, conservative means of diagnosing tuberculosis in children. The results of magnetic resonance spectroscopy (MRS) reveal pronounced lipid levels in the metabolites, an indicator of TB. Tuberculosis is the only bacillus that contains lipid in its cell membrane. Our idea for this new diagnostic approach and its successful implementation has been published in the European Journal of Medicine. Further publications are pending.



This 25-day-old girl was in a coma when she was brought to our hospital. The fish-shaped growth in her brain is an abscess. Here too the diagnosis of tuberculosis was confirmed by magnetic resonance spectroscopy (MRS). In both these children, the diagnosis was further confirmed from a sample of pus collected in a surgical intervention and tested by GeneXpert (molecular biology analysis). During the Khmer Rouge regime, 300 prisons and concentration camps were maintained in Cambodia, and they were breeding grounds for tuberculosis. Young mothers who are infected by tuberculosis, but do not yet exhibit symptoms of the disease, may pass the infection to their infants at birth. Thus many thousands of children still suffer from tuberculosis today, a legacy left behind by the Khmer Rouge. In 2010 the Kantha Bopha Children's Hospitals diagnosed and treated 22,500 cases of tuberculosis, and in 2011, it was 21,000 cases. The course of the disease is more severe in children who are vaccinated against TB with BCG. It is a mistake for the World Health Organization (WHO) to promote and conduct BCG vaccinations in poor countries. Due to the inadequate and in some cases fatal WHO protocols for diagnosing tuberculosis (which must be followed in order to qualify for support from the HIV/TB/malaria fund in Geneva), tuberculosis is overlooked in children. Children do not produce the sputum on which the WHO bases its diagnosis of TB. But the disease is present in children as well and, if left untreated, it leads to deformities and death. Only with your help are we able to continue our efforts to detect and treat tuberculosis in children. Children who receive treatment, which takes one year, make lasting recoveries. During the last 20 years we have never had a case of re-infection. Every Swiss franc you give helps to heal and prevent illness and save lives. We thank you from the bottom of our hearts.