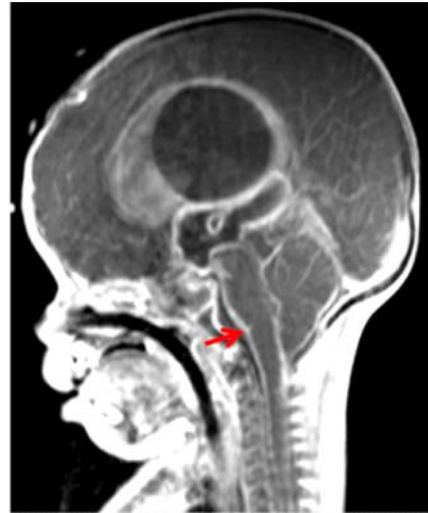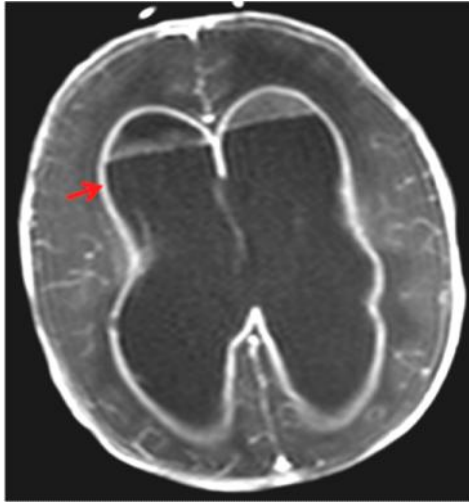


# The deadly Tuberculosis of the Newborn



This only 25-day old child was hospitalized in Battambang as it was 11 days old. There it was not done a correct diagnosis. So the child has got a wrong treatment and has arrived in Jayavarman VII (Kantha Bopha III) in Siem Reap Angkor in a catastrophic state as it was 25 days old.

By MRI we find a huge inflammation of the cervical spinal cord, of the ventricles in the brain. The ventricles are enlarged (Hydrocephalus) as a consequence of the Meningitis. By MRS and the spinal fluid we can do the diagnosis of Tuberculosis.

The mother is 21-year old. She is in best health. But we find by computer tomography the Primary Complex of Tuberculosis (dormant Tuberculosis). At the end of the pregnancy the immunity of the mother gets to be reduced in order not to loose the child too early. At the end of pregnancy the child gets to be a foreign body and could be lost by the normal immunity of the mother fighting against every foreign body. The reduced immunity can destabilize the Primary Complex and the germ TB gets in the blood stream and can even enter the not yet born child, as it happened in the case above. After birth the immunity of the mother is normalized immediately. The young mother doesn't get to be sick.

Older people have a reduced immunity. So their Primary Complex is more and more destabilized and these older people start to suffer from active Tuberculosis contaminating others.

The same happens to young people with a Primary Complex as soon they are contaminated by HIV, what is causing an immunity depression.

The 25-day old child got the vaccination BCG. When the ministry of Health, the WHO and Unicef will stop this ineffective and dangerous vaccination? Why they stopped it only in the rich world?

Dr. Beat Richner, founder and head of the Kantha Bopha Hospitals, 11.4.2014